



PATIENT PRESENTING CLINICAL SIGNS

Lizzy Fox History: Acute onset hemorrhagic enteritis. Previous history of chronic pancreatitis.

SPECIES Physical Examination: N/A.

Canine Urinalysis: N/A.

CBC: N/A.

BREED Serum Biochemistry: N/A.

Poodle Radiographic Findings: N/A.

SEX ULTRASONOGRAPHIC EXAMINATION OF THE ABDOMEN

FS **Urinary System**

Age Full urinary bladder with a normal thickness and echogenic appearance of the wall. Normal anechoic urine with no sediment or uroliths evident.

9 years Normal trigone area, proximal urethra (0.6 cm), and iliac blood vessels.

WEIGHT Normal iliac lymph nodes (2.3 cm). Ureters not visualized.

45 # Normal renal size (left 6 cm, right 5.3 cm), echogenic appearance, cortico-medullary differentiation, pelvis, and capsule.

INTERPRETED BY **Reproductive System**

Remo Lobetti, BVSc,
MMedVet (Med), PhD, Dipl.
ECVIM

N/A.

Adrenal Glands

Normal position, echogenic appearance, size, and shape. Left 0.6/0.44 cm, right 0.51/0.7 cm.

Spleen

Normal size (2 cm) and echogenic appearance. Smooth homogenous parenchyma, normal vasculature, and regular curvilinear capsule. No evidence of inflammatory, neoplastic, infarction, or infiltrative changes noted.

Liver

Normal size, echogenic appearance, portal markings, and regular curvilinear capsule. No nodules or masses evident. Full gall bladder containing normal anechoic bile. Normal thickness and echogenic appearance of the gall bladder wall. Normal bile duct (0.2 cm).

Gastrointestinal

Normal appearance of the duodenum, small intestine, and colon with no loss of layering, normal wall thickness (duodenum 0.37 cm, jejunum 0.34 cm, colon 0.25 cm) and peristaltic activity, and no distension of the lumen. Thickening of the gastric wall (0.6 cm) with no loss of layering. Fluid filled stomach.

INVOICE

303849

DATE

2/2/23

IMAGING PERFORMED BY

Sonya Myers, DVM

HOSPITAL NAME

Oviedo Veterinary Care and
Emergency

REFERRING VET

Dr Caja



PATIENT

Pancreas

Lizzy Fox

Enlarged, especially the left lobe (1.1 x 3.1 cm) with a hypoechogenic appearance. Irregular capsule. Hyperechogenic appearance of the mesentery and fat surrounding the pancreas.

SPECIES

Free Abdomen

Canine

Normal mesenteric lymph nodes (3.8 cm).
No ascites.

BREED

Poodle

ULTRASONOGRAPHIC FINDINGS

Primary Findings:

SEX

FS

- Pancreatitis.
- Gastropathy.

Age

9 years

Secondary Findings:

- None.

WEIGHT

45 #

INTERPRETATION OF THE FINDINGS & FURTHER RECOMMENDATIONS

Etiologies for the gastropathy would be secondary to the pancreatitis, non-specific (toxins, dietary indiscretion), helminths, *Helicobacter* gastritis, ulcerative disease, and inflammatory bowel disease.

Further assessment would be fecal analysis, cPL/PSL assay, and if there is not a satisfactory improvement then gastroscopy with biopsies.

Management would be fluid therapy, corrected of electrolyte anomalies (as needed), anti-emetics, gastric protectants, and opioid analgesics.

INTERPRETED BY

Remo Lobetti, BVSc,
MMedVet (Med), PhD, Dipl.
ECVIM

IMAGING PERFORMED BY

Sonya Myers, DVM

HOSPITAL NAME

Oviedo Veterinary Care and
Emergency

REFERRING VET

Dr Caja

INVOICE

303849

DATE

2/2/23



PATIENT

Lizzy Fox

SPECIES

Canine

BREED

Poodle

SEX

FS

Age

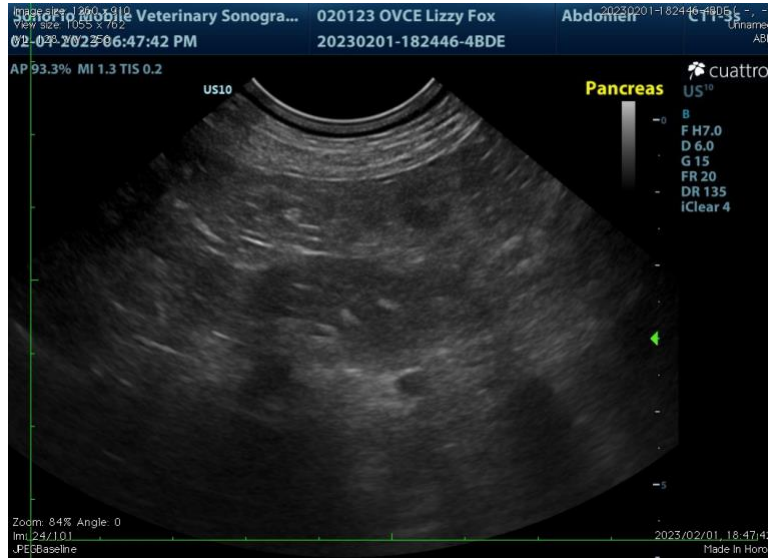9 years

WEIGHT

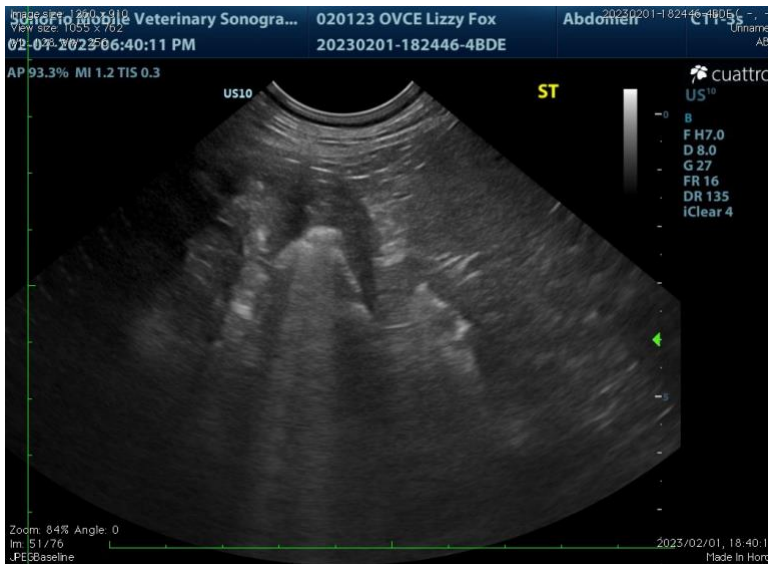
45 #

IMAGES

Pancreas



Stomach



INTERPRETED BY

Remo Lobetti, BVSc, MMedVet (Med), PhD, Dipl. ECVIM

IMAGING PERFORMED BY

Sonya Myers, DVM

HOSPITAL NAME

Oviedo Veterinary Care and Emergency

REFERRING VET

Dr Caja

INVOICE

303849

DATE

2/2/23

The information and recommendations provided are based on the images presented by the referring veterinarian. No evaluation can be communicated regarding pathology that was not visible in the image/video clips provided.

Thank you for this referral. If the clinical or image interpretation does not parallel your findings or if I can be of any further assistance, please contact me.

Remo Lobetti, BVSc, MMedVet (Med), PhD, Dipl. ECVIM (Internal Medicine)
rlobetti@mweb.co.za